

Case Report - Dr. med. dent. Steffen Ulbrich, St. Gallen, Switzerland

In a heavy smoker - Biodenta[®]-Implant placement

Introduction

There is often the question in daily practice: Shall we place dental implants in heavy smokers? Scientific literature shows evidence of an increased risk of failure when smoking more than 15 cigarettes per day. In the EU 35% of the adult population smokes. As the principle clinician I am confronted every day with this exact issue. The following case report documents the implant therapy in a heavy smoker and the management of the complications.

Case Report

A 38years old male patient wishes to replace the lost tooth #46. This tooth was extracted three years ago due to an endodontic failure. The radiographic examination (panoramic) shows sufficient vertical bone height.

The patient is in generally good health. A thorough dental examination confirms healthy periodontal tissues, optimal restorations and no decay present.

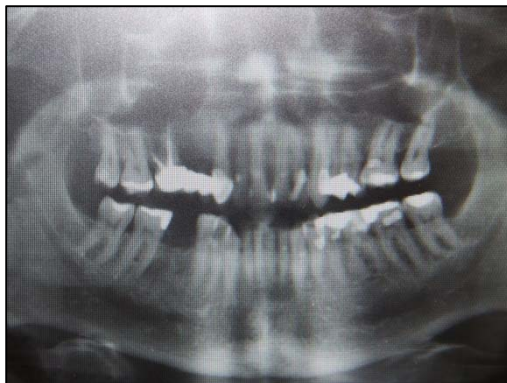

Fig. 4: Panoramic radiograph at examination

The patient smokes 20 cigarettes per day and is not willing to change his smoking habit. This increases the failure risk significantly. After a lengthy consultation the patient was informed about this specific risk.

The implant surgery was uneventful. After a small crestal incision and raising a small flap a Biodenta[®]-Tissuelevel-Implant (ø4.1/12mm) was placed and submerged. The primary stability was optimal (35 Ncm). The bone volume was more than sufficient and therefore no grafting was required. Finally the wound was closed with Vicryl 5/0 sutures.

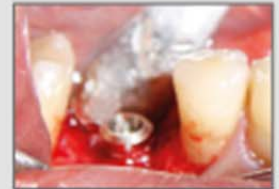

Fig. 1:
Final position of the implant

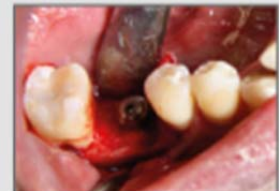

Fig. 2:
Closure screw installation

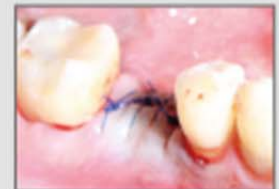

Fig. 3:
Wound-closure with Vicryl 5/0 sutures!

Case Report - Dr. med. dent. Steffen Ulbrich, St. Gallen, Switzerland

A follow-up review was conducted and a peri-apical radiograph was taken revealing peri-implantitis surrounding the implant #46. The peri-apical as well as the panoramic radiograph (Fig. 5 and 6) shows 3 mm of bone loss mesial and distal of the implant. The patient has no discomfort to date.

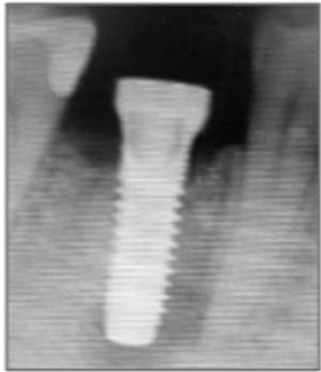

Fig. 5: Follow-up radiograph

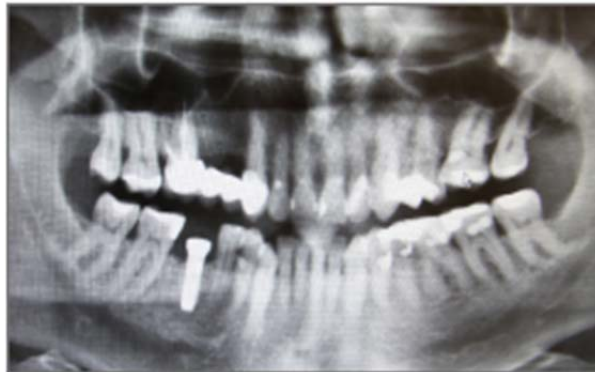

Fig. 6: Panoramic radiograph two months after implant insertion.

After raising a small sub-periosteal flap moderate circular and horizontal bone loss was detected around the implant.

The granulation tissue was thoroughly removed with a plastic implant-curette.

The exposed implant surface was rinsed with a phosphor-acid solution (20%) for 30 seconds followed by saline solution for another minute. The bony defect was filled similar to the conventional GBR technique with an alloplastic bone filler and covered with a collagen membrane. Figures 7 and 8 radiograph illustrate the post-surgical bone level.

The patient is again advised to reduce smoking and to follow the strict oral hygiene protocol. A two-month recall with the dental hygienist has also been advised.

Oral antibiotics were prescribed as the standard protocol. The coverage over 5 days is essential in this situation. A post-operative mouthwash was also prescribed to the patient, as a part of their oral hygiene protocol.

A follow-up review after seven months presented a completely healed site. The soft-tissues did not show any signs of inflammation (Fig. 9 und 10).

The restorative rehabilitation phase was now ready to commence.

An alginate impression was taken in order to fabricate a special tray for the secondary master impression.

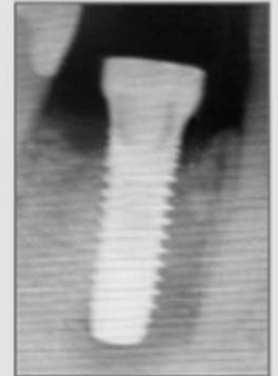

Fig. 7:
Detail of the Radiograph after the GBR.

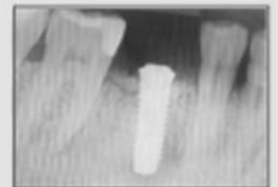


Fig. 8:
Radiograph after the GBR.

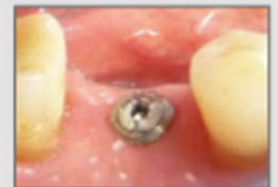

Fig. 9:
Implant after osseointegration

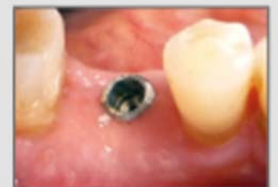

Fig. 10:
Implant after osseointegration

Case Report - Dr. med. dent. Steffen Ulbrich, St. Gallen, Switzerland

A secondary impression was taken by using a special tray and poly-ether material.

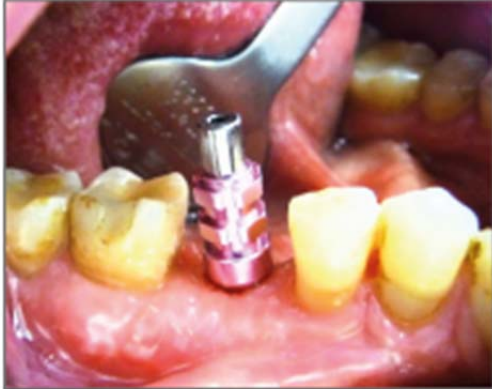

Fig. 11: Screw-retained impression coping in situ

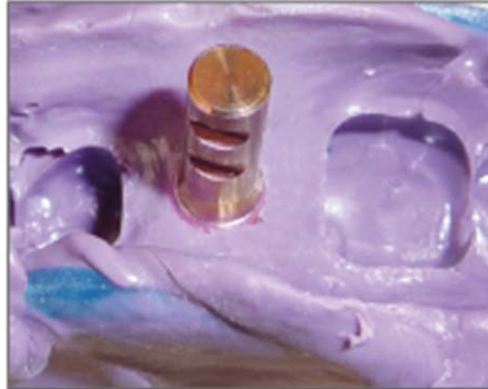

Fig. 12a: Detail of the impression

A working model with the implant replica was fabricated.

A plastic cylinder for a single tooth restoration was selected.

The cylinder underwent a wax-up procedure.

The wax-up was scanned and a CAD/CAM milled Zirconia coping was fabricated.

For the direct porcelain overlay of the Zirconia coping the ceramics2in1 - porcelain from Biodenta was used. Ceramics2in1 can be used for firing on titanium and Zirconia.

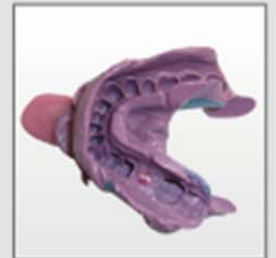

Fig. 12:
Impression with poly-ether material



Fig. 13:
Prosthetic components:

- a. Plastic cylinder
- b. Straight abutment
- c. Abutment screw

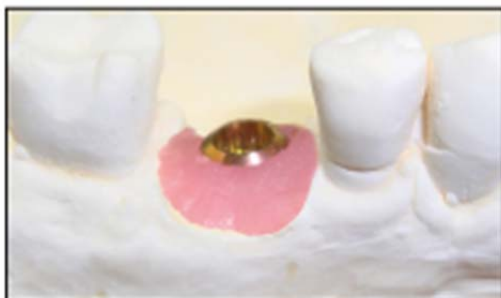

Fig. 14: Model with gingival mask



Fig. 15: Implant replica



Fig. 18:
Straight abutment

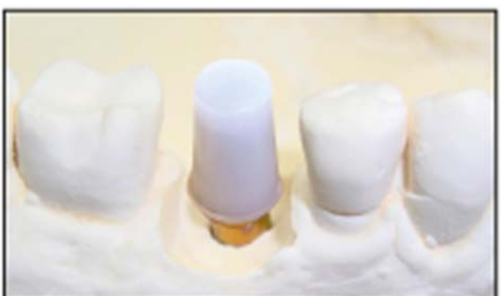

Fig. 16: Plastic cylinder

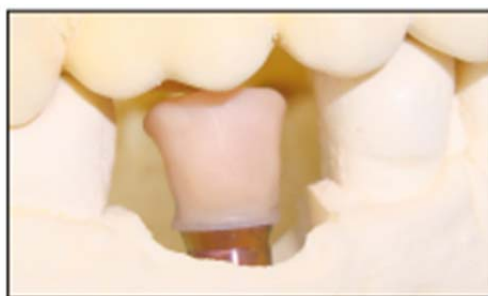

Fig. 17: The milled and coloured coping is ready for the porcelain application with „ceramics 2in1“.

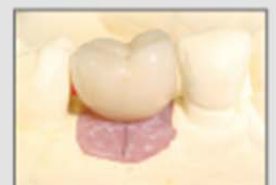

Fig. 19:
Completed restoration

Case Report - Dr. med. dent. Steffen Ulbrich, St. Gallen, Switzerland

The straight abutment was inserted with a standard torque of 35Ncm (Fig. 20). The screw access canal was sealed with a cotton pellet and hydro-wax. Cementation of the crown followed with a provisional cement.

The final radiograph shows a perfect fit (Fig. 23).

As you can see in the illustration of Fig. 23 the bone graft has completely healed within the osseous site.

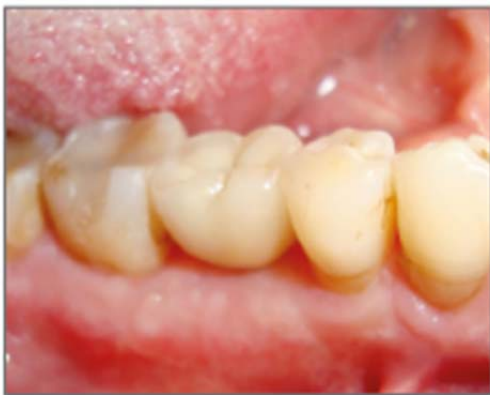

Fig. 21: Cementation of completed implant crown #46

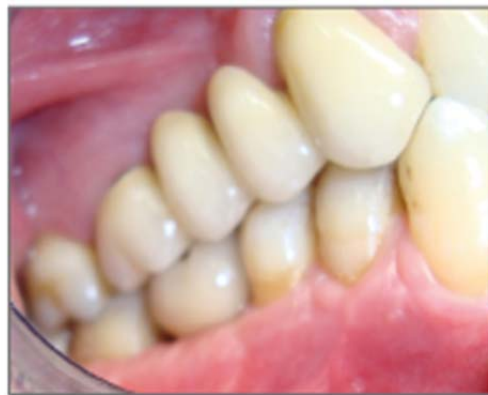

Fig. 22: Review of the occlusion

Discussion

Scientific literature states different risk factors that may cause peri-implantitis. One of these contributing factors is smoking. This does have negative influence on the vascular perfusion.

This case report shows that complications can be solved with standard procedures.

Importance of regular follow-up reviews is essential in order to detect the possibility of peri-implantitis in an early stage.

The potential of bone regeneration surrounding the implant is an important factor to consider.

The maintenance is a crucial factor in the long term success of implant osseointegration and should be reviewed in half-year intervals.

Clinician

Dr. med. Dent. Steffen Ulbrich is a member of the ITI group and the AACD.

Dr. med. Dent. Steffen Ulbrich is a Consultant within Prof. Sailer's Clinic in Zurich.

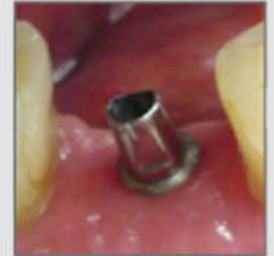

Fig. 20:
Straight abutment in situ.

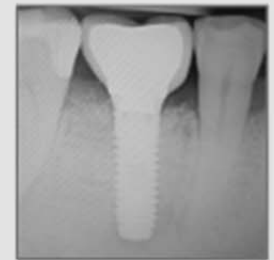

Fig. 23:
Radiograph after the delivery
of the implant crown.



Dr. med. dent. Steffen Ulbrich