

Case Report - Dr. Arthur Weiss

High Esthetic Solutions with a Team Approach to Implant Dentistry The placement of hybrid abutments in the highly esthetic anterior zone

Introduction

Proper planning with a team approach ensures that highly esthetic results can be accomplished in the esthetic zone with the placement of consecutive implants. The use of the hybrid abutment allows both functional and esthetic superiority.

Case Report

The patient, presented to the office with a history of trauma to the maxillary anterior centrals, tooth numbers 8 and 9. As a child, the patient was involved in an accident resulting in subsequent endodontic treatment and periapical surgery with a retrograde amalgam on tooth #9. The patient was quite unhappy with the esthetics of the previous dental treatment in this highly visible area of the mouth. There was discoloration at the cervical aspects of the two crowns and she was experiencing drainage from the upper teeth (Fig.1). The patient was concerned about the potential of losing one or both of these teeth and an inability to have an adequate replacement, especially if an emergency situation developed. The patient wanted to take a proactive position to ensure that they would not suffer the embarrassment of missing anterior teeth. The initial comprehensive exam included full mouth X-rays, periodontal probing, hard and soft tissue analysis, and an occlusal exam, with an emphasis on the patient's chief complaint. The patient's X-rays revealed quite bulbous, short roots with a retrograde amalgam on tooth #9 and a small periapical lesion from where the drainage originated (Fig. 2). There was 4 to 5mm probing around these teeth but otherwise the patient had a good periodontal presentation. The crown to root ratio is reversed by almost a 2 to 1 presentation. Additionally, the patient had a fairly high lip-line presenting a gummy smile (Fig. 3). Interestingly enough, however, this was not a major concern to the patient. However, in consideration of the various esthetic options, this was an emphasized part of the treatment plan presentation. Ultimately, the case involved the integration of three different practitioners: Oral & Maxillofacial Surgeon; Orthodontist; and Restorative Dentist (self). The patient was referred to and diagnosed by all doctors involved. The practitioners met to discuss the case, independent of the patient, presenting the various pros/cons and negative sequelae of the different options for treatment. Diagnostic aids used were 3D Cone-beam, digital X-Rays, articulated/mounted study models and photographs (Fig.4).

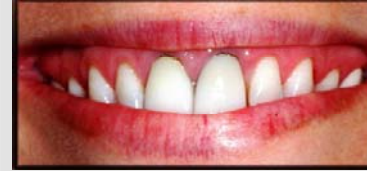

Fig. 1: Pre op

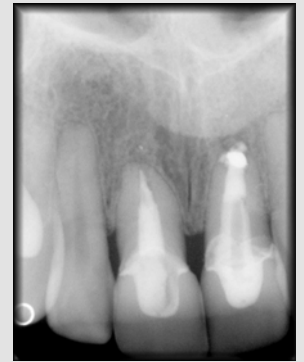

Fig. 2: Pre op

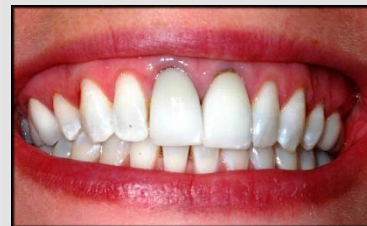

Fig. 3: Pre op

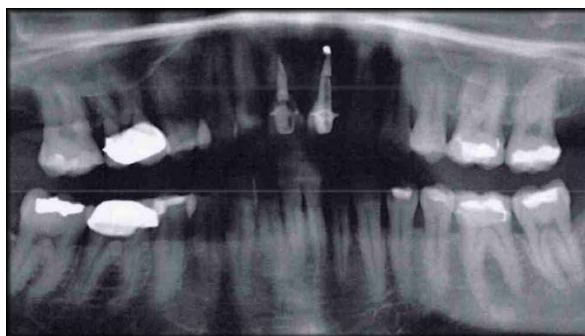


Fig. 4: Full mouth scan

Case Report - Dr. Arthur Weiss

During the time these discussions regarding the evolution of the patient's treatment plan were taking place, the patient was treated to improve overall periodontal and dental health. She received site specific scaling and root planning and, as an adjunct, the placement of Arestin (local oral antibiotic) in the periodontal sulcus around tooth #9). The patient was also placed on a three month "Re-care" to ensure healing, diminution, and removal of any potential infection in the area that could negatively impact the decision to place implants as the treatment of choice.

One of the primary concerns was the relative height of the bone currently between tooth numbers 8 and 9 and the adjacent teeth. Extracting the teeth and placing the implants posed a risk of losing central incisor interproximal bone, and therefore papillary tissue, which would negatively affect the final esthetics. Maintaining the bone through the procedures of extraction, implant placement, provisionalization, and final crown placement needed to be carefully addressed and handled effectively. Special attention was given to ensuring the appropriate distance from the crest of bone to the crown contact area in order to avoid "the dreaded black triangle" or short papilla in the cervical embrasure. There was also an unesthetic size discrepancy between the central and the lateral incisors. Various options were presented to the patient to try to maximize the esthetic placement of implants for tooth #8 and #9. These options included Orthognathic surgery, orthodontic treatment, and reduction of the gummy smile.

However, since this was not a priority for the patient, and both cost and time made this prohibitive, this was not a treatment alternative the patient was willing to accept at this point. Another alternative was presented in which we would intrude tooth numbers 6, 7, 10, and 11, and slowly extruded tooth numbers 8 and 9. This treatment concept was presented in order to bring the bone heights more incisally for #8 and #9. It was also to raise the gingival margin apically for the anterior segment, while anticipating bone height and papillae development around numbers 8 and 9 after implant placement and healing. The goal was to ensure that, when the implants were placed and integrated, we would have an excellent esthetic and functional relationship with all the teeth involved.

The patient elected to move forward with this treatment plan. During the orthodontic treatment, the incisal edges of numbers 8 and 9 were reduced sequentially to keep them in line with the other teeth and allow for further eruption (Fig.5). The area was periodically monitored to observe the bone height relative to each tooth, the anticipated CEJ, and the contact zones. Periodic reassessment confirmed that the localized infection was eliminated and the patient was maintaining not only adequate, but exceptional periodontal health.

Prior to starting the orthodontic treatment, it should be noted that a waxed model representation of the final esthetic case was constructed (Fig.6). This would ensure that the patient was accepting of the final esthetics and provided a template for immediate temporization following implant placement. We would thus have an adequate provisional fabricated to be placed on the teeth. The patient was evaluated at the end of orthodontic treatment, prior to removal of any ligatures and wires, to ensure that we had adequate movement of the teeth with attending bone to be able to place the implants. All practitioners also ensured that the surgical and restorative sites were as desired. They were asymptomatic, without drainage, and tissue health was again highly well developed and maintained by the patient. A wire splint was placed on the palatal aspect of the teeth. Final assessments were made. Surgical and restorative preparations and coordinated appointments were made for the patient. Implants were placed by the surgeon (Figs. 7 and 8) and the patient was then immediately sent to my clinic for placement of temporary abutments. At that time, an immediate implant level impression was taken with the open tray

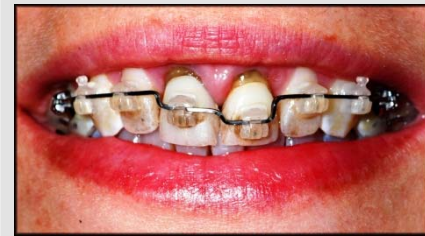

Fig. 5: Orthodontic treatment

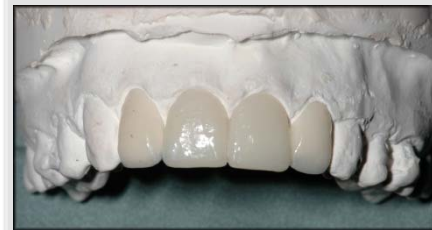

Fig. 6: Waxed model

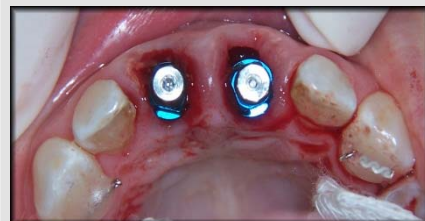

Fig. 7: Implant placement

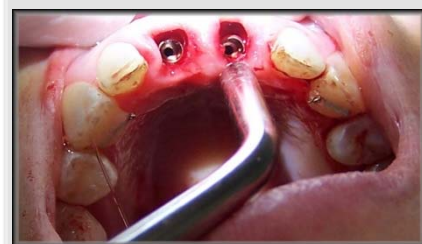

Fig. 8: Implant placement

Case Report - Dr. Arthur Weiss

technique. This technique, in my view, ensures the least amount of stress placed on the implants when the impression is removed since the impression coping is unscrewed prior to the removal of the impression and the tray is passively removed (Fig. 9). This technique was also chosen due to the angulation and height of the apically placed tissue level implant in the alveolus to maximize retention, for immediate temporization.

After taking an immediate implant level impression, the case was sent to a Biodenta partner laboratory. The laboratory was previously informed of the need for temporary crowns with integrated abutments to be finished quickly and they produced the product accordingly. In this particular situation, we had also decided to place temporary veneers on numbers 7 and 10 to balance the esthetic dimensions of the teeth (Fig 10). Secondly, placement of veneers on these teeth would allow ideal development of the gingival tissues and interdental papillae. The temporary crowns were fabricated and arrived at the office a few days after the patient's surgery. The immediate temporaries were inserted as a two unit bridge stabilizing the implants. These were designed out of occlusion (Fig. 11). We left the distal ends of both of these teeth slightly larger so they could be re-contoured with the later placement of the temporary veneers which were also fabricated at this time. We did not prepare veneers in a healing surgical site to ensure that no debris was introduced to the area.

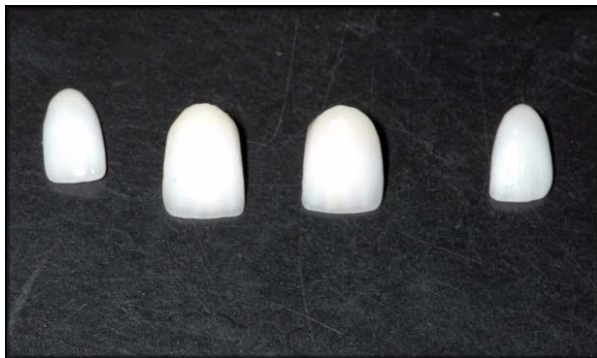

Fig.10: Veneers

When the patient returned for placement of the temporary abutment, the excellent placement and location of the implants required only a very slight modification of the temporaries to adequately screw those into place (Fig. 12). The labial surface had a slight defect in the processed composite material for screw access and was closed with a blended composite resin. Upon the reassessment of the healing, tooth numbers 7 and 10 were prepared for veneers in an ideal preparation.

The use of prefabricated, processed, composite veneers required these to be permanently bonded even though they were being employed in a temporary fashion. The permanent bonding allowed for the retro-fitting of the previously fabricated veneer. It also allowed for filling any voids that may have existed for an intimate fit of the restoration and the tooth. The placement of the veneers, after the re-contouring of the distal aspect of the temporary crowns, allowed for maximal tissue development without the introduction of bacteria associated with temporary cementation.

The patient was monitored periodically and it was decided that a very slight gingival re-contouring needed to be done. This was accomplished from the distal of #6 to the distal of #11. The re-contouring allowed for a slightly better esthetic presentation and to bring the tissue height more in line with the biologic width considerations. Upon healing of the tissue,

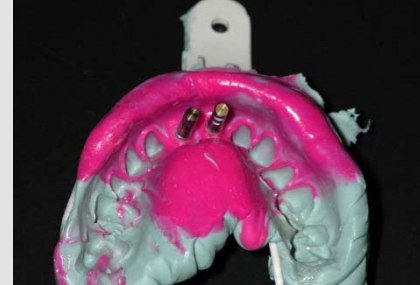

Fig. 9: Impression Technique

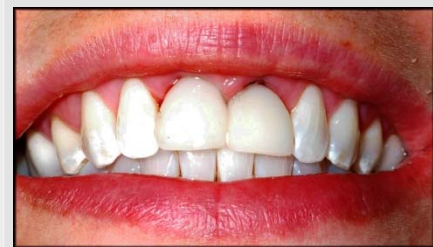

Fig.11: Temporaries

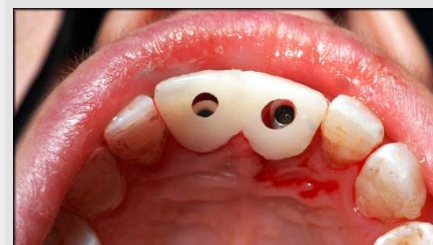

Fig.12: Temporaries

Case Report - Dr. Arthur Weiss

we discussed various esthetic concerns that the patient may have had. The patient decided to whiten her teeth during this time of healing.

The time frame of this case was very interesting and much shorter than we initially contemplated. It took approximately nine months from the beginning of orthodontic treatment to the placement of the implants. It then took approximately six to seven months for the finalization of the case. Adequate healing was allowed following the laser gingivectomy and tissue re-contouring (Fig 13). A final impression was taken for the placement of the implant crowns. At that time, the temporary veneers were removed. Given the fact that the teeth had already been prepared, the amount of time to remove the temporaries and redefine the preparations was very quick and very simple. A new implant level impression was taken.

This enabled us to capture the detail of the veneer preparations in relation to the implants and, most importantly, the relationship of the gingival tissue. As would be expected, the implants were stable and did not shift. Therefore, we had the same relationship with the abutments that were placed earlier. The abutments chosen were the DentaSwiss 'Hybrid' abutment (Fig. 14). This abutment has a titanium base with a zirconia insert providing a very tight titanium-to-titanium integration and fit yet with the advantages of the zirconia material, strength, and esthetic options (Fig.15). Once screwed into place it acts very similar to a pressure fitting in a plumbing valve (Fig. 16). The use of the titanium base followed by the zirconia insert and abutment allows a highly esthetic restoration to be placed as well as to eliminate the problems of fretting with dissimilar materials since we have a titanium implant and a titanium abutment in contact with one another. A zirconia crown with the DentaSwiss 'Ceramics2in1' porcelain was placed. This porcelain was chosen due to its physical properties (coefficients of thermal expansion similar to zirconia) and esthetics allowing an almost identical match to the feldspathic porcelain material that was used on the veneers for numbers 7 and 10.

The abutments and crowns were placed in the mouth and verified for fit radiographically. The veneers were also verified for fit and then shown to the patient for esthetic approval. The veneers were bonded in place using clear 'Insure' resin cement by Cosmedent. The 'Hybrid' abutments were screwed into place and torqued to 35 ncm. At the time of placement of the 'Hybrid' abutment, a cotton pellet was placed in the screw access space followed by a light cured onlay temporary material fabricated by 'Cosmedent'. This allows for easy retrievability, if needed. It is also hand sculptable to ensure that there is no impingement on the internal aspects of the crown and serves the purpose very well.

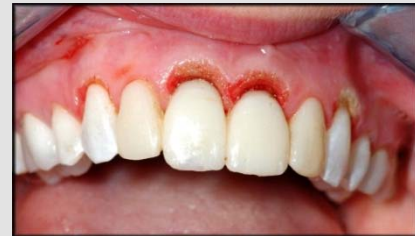

Fig. 13: Laser Gingivectomy

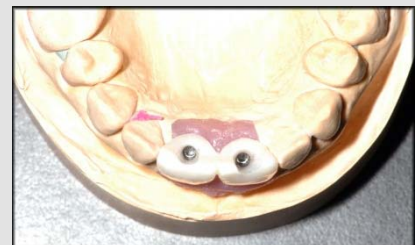

Fig. 14: Temporary bridge

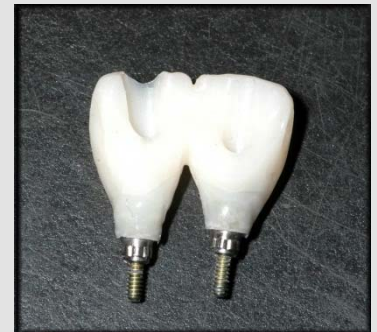

Fig.15.Temporary bridge

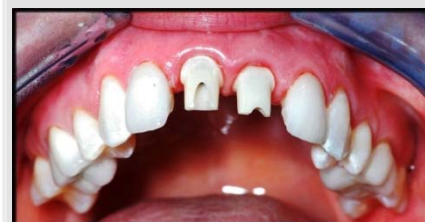

Fig. 16: Hybrid abutments

Case Report - Dr. Arthur Weiss

Finally, the crowns were placed with 'TempBond Clear' by Kerr, clear temporary cement (Figs. 17 and 18). This material allows for retrievability and access to the abutment. Additionally, it allows one to monitor the tissue adaptation and functionality of the restorations allowing for changes, if needed, prior to finalization. The result was amazingly beautiful. The patient was extremely happy with the results of the treatment. She was examined again 10 days post-operatively.

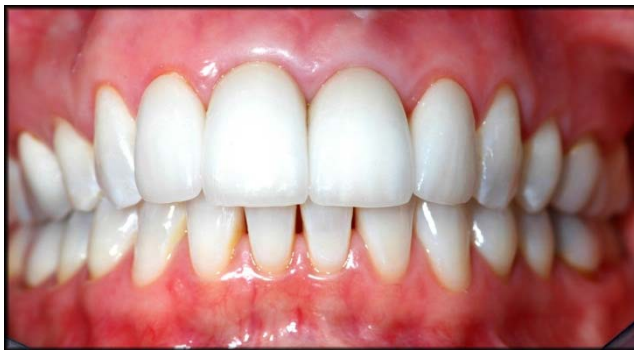

Fig. 18: Final Crowns

At the time of the post-operative visit, the occlusion was checked again to ensure there were no unwanted contacts or excursive movements, and the tissue was re-evaluated. The tissue was well within normal limits and the papilla development was where it was expected to be. The patient was seen again in a few weeks for her normal hygiene visit and maintenance and follow-up. Post treatment instructions were reinforced with the patient and final photographs were taken (Fig. 19).

Discussion

Success is predicated on a coordinated team approach with the appropriate armamentarium to deliver the optimum in care. Ultimate success is measured in a variety of ways. The most important in esthetically driven treatment is the patient's view that, not only were her goals clearly exceeded, but that she has the highest levels of confidence to smile.

Clinician

Dr. Arthur Weiss of Rockville, Maryland, USA

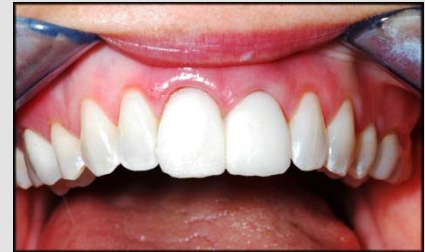

Fig. 17: Final Crowns

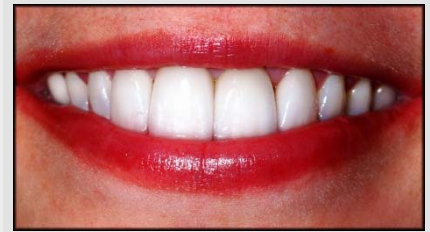

Fig. 19: 1 year post op



Dr. Arthur Weiss